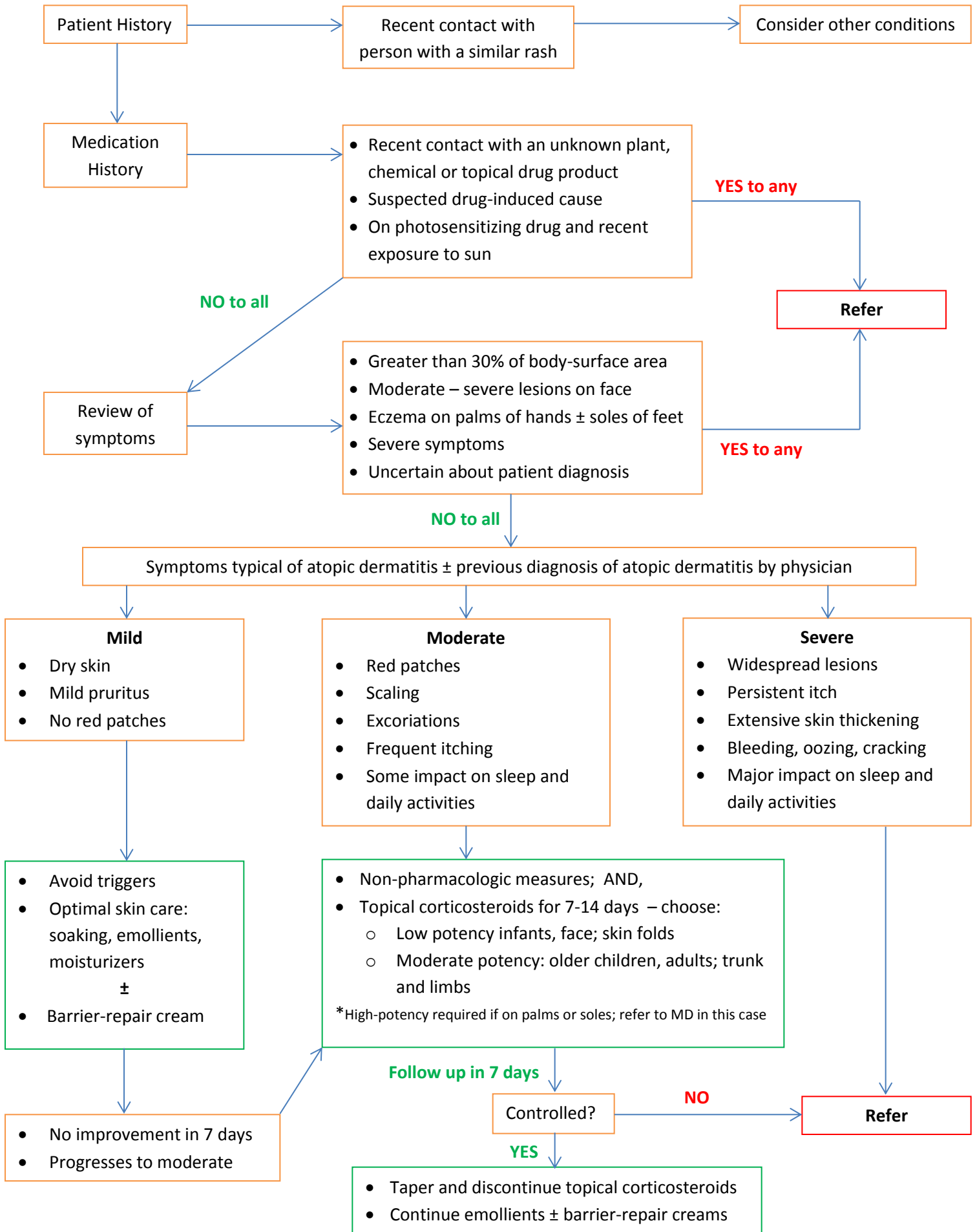


# ATOPIC DERMATITIS



Patient History

Recent contact with person with a similar rash

Consider other conditions

Medication History

- Recent contact with an unknown plant, chemical or topical drug product
- Suspected drug-induced cause
- On photosensitizing drug and recent exposure to sun

YES to any

NO to all

Refer

Review of symptoms

- Greater than 30% of body-surface area
- Moderate – severe lesions on face
- Eczema on palms of hands ± soles of feet
- Severe symptoms
- Uncertain about patient diagnosis

YES to any

NO to all

Symptoms typical of atopic dermatitis ± previous diagnosis of atopic dermatitis by physician

- Mild**
- Dry skin
  - Mild pruritus
  - No red patches

- Moderate**
- Red patches
  - Scaling
  - Excoriations
  - Frequent itching
  - Some impact on sleep and daily activities

- Severe**
- Widespread lesions
  - Persistent itch
  - Extensive skin thickening
  - Bleeding, oozing, cracking
  - Major impact on sleep and daily activities

- Avoid triggers
- Optimal skin care: soaking, emollients, moisturizers ±
- Barrier-repair cream

- Non-pharmacologic measures; AND,
- Topical corticosteroids for 7-14 days – choose:
  - Low potency infants, face; skin folds
  - Moderate potency: older children, adults; trunk and limbs
- \*High-potency required if on palms or soles; refer to MD in this case

- No improvement in 7 days
- Progresses to moderate

Follow up in 7 days

Controlled?

NO

Refer

YES

- Taper and discontinue topical corticosteroids
- Continue emollients ± barrier-repair creams